

Evaluation of Toxic Impacts of Mancozeb on Testis in Rats

Suresh C. Joshi*, Nandan Gulati, Anita Gajraj

Reproductive Toxicology Unit, Department of Zoology

Department of Zoology, University of Rajasthan, Jaipur 302004, India

Abstract : These days pollution of the environment by pesticides is a problem of great importance and is of everybody's concern. Mancozeb, a fungicide, was listed for male reproductive toxicity. The fungicide was administered to Wistar strain male albino rats orally at the dose level of 500 mg/kg b.wt./day for 30 days. Sex organ weight analysis, fertility, biochemical and enzymatic parameters and testosterone level were the criteria used to evaluate the toxicity of Mancozeb on treated rats. The weight of testis, epididymis, seminal vesicle, and ventral prostate decreased significantly. Mancozeb treatment also brought about marked reduction in epididymis and testicular sperm counts in exposed males. Pre- and post-fertility test showed 80% negative results after treatment. A significant reduction in the testicular glycogen and sialic acid was observed whereas a significant increase in the protein and cholesterol content of testis was noticed. In addition, acid phosphatase enzyme activity increased significantly while alkaline phosphatase activity showed a sharp decline. Mancozeb also suppressed testosterone level significantly. In conclusion, Mancozeb exerts toxic effects on testis of rats.

Key words : Mancozeb, testis, sperm dynamics, testosterone.

Introduction

The ever increasing problem of population since last few decades has put tremendous pressure on land. To feed the galloping population, there is a shift in cultivation of recalcitrant varieties to high yielding varieties and this is followed by a sizable variety of invading pests (Giridhar and Indira, 1997). To subvert these pests, variety of pesticides came to picture, one of these are fungicides. These were hailed as miracles of modern technology. Given today's extensive use of pesticides it is almost impossible for any one to avoid daily exposure to low level of several different pesticide residues. Pesticide incidents have more than doubled in the last 10 years. Each year 3 million people are poisoned by pesticides with 2,20,000 deaths (WHO, 1997).

* Corresponding Author Suresh C. Joshi Associate Professor, Ratnadeep, 170, Vishwakarma Nagar- I, Maharani Farm, Durgapura, Jaipur – 302018 (INDIA)
E-mail: s_c_joshi2003@rediffmail.com; **Phone:** +91-141-2762525 **Fax:** +91-141-2740141

The most direct and most hazardous exposures occur among those who manufacture and formulate them, or apply them, or live or work near the areas where they are used heavily (Skjei & Donald, 1983), which may have cumulative effects that lead to reproductive disorders (Lafuente *et al.*, 2000). Introduction of new more toxic and rapidly disseminating pesticides into environment has necessitated accurate identification of their potential hazards to human health. Many pesticides are extremely toxic to mammals and other non-target organisms (Ankley & Jensen, 2001).

Studies are underway to address concern of potential persistent immunotoxic, reproductive, and neurotoxic effects of chronic and acute exposure to several pesticides. It is reported that pesticides may induce pathological changes in the testes and liver of rats (Dikshith and Datta, 1972; Joshi *et al.*, 2003). Reproductive hormone profile among pesticide factory workers also have been reviewed (Padungtod *et al.*, 1998). Occupational exposure to pesticides has increased parental risk of infertility whereas less is known about residential use of pesticides and the risk they pose to reproduction and development (Greenlee *et al.*, 2004).

Mancozeb, an Inorganic-Zinc dithiocarbamate, is a typical fungicide with a carbamate structure where sulphurs replace both oxygens in the amide functional group. It is chemically identified as ethylenebisdithiocarbamate (EBDC). The poisoning caused with EBDC compounds cause symptoms of irritation of skin, eyes and respiratory tract, skin sensitization; chronic skin disease has also been observed in occupationally exposed workers. Mancozeb exposure is associated with pathomorphological changes in liver, brain and kidney. It has produced significant enzymatic changes in the activities of various enzymes (Kackar *et al.*, 1999). Inhibition of implantation by Mancozeb due to hormonal imbalance or its toxic effects has been studied (Bindali and Kaliwal, 2002). However, only few attempts have been made to observe the effects of Mancozeb on male reproductive system. Hence, present investigation was chosen to evaluate the testicular toxicity induced by Mancozeb in rats.

Material and Methods

Animal Model : Healthy adult male albino rats (*Rattus norvegicus*, Wistar Strain) of an average body weight 150-200 gms have been employed

for experimentation. The animals were kept in clean polypropylene cages covered with chrome plates grills and maintained in an airy room with controlled room temperature of ($20^{\circ}\text{C} \pm 5^{\circ}\text{C}$) with 14 : 10 hours light and dark cycle. The animals were mostly maintained on standard pellet diet procured from Ashirwad Industries, Chandigarh and occasionally on germinated/ sprouted gram and wheat seeds as an alternative feed. They were given clean water *ad libitum*.

Test Material and Dose : Technical grade Mancozeb (Ethylenebisdithiocarbamate / Inorganic-Zinc dithiocarbamate) obtained from Gupta chemicals Pvt. Ltd. Jaipur, was used for experimentation. The fungicide was administered to male rats through oral intubation at the dose level of 500 mg /kg b.wt./day for 30 days.

Experimental Procedure : Animals were divided into two groups having 6 animals each. Group I animals were kept as control and were administered olive oil only whereas animals of Group II were treated with the desired test compound at decided dose level. At the end of the experimentation, the rats were weighed, sacrificed under light ether anesthesia. The male reproductive organs were removed, weighed and processed for detailed biochemical and histopathological studies.

Fertility Test : The mating exposure test of the animals was performed. They were cohabited with proestrous females in the ratio of 1:3. The vaginal plug and presence of sperms in the vaginal smear was checked for positive mating. Females were separated and resultant pregnancies were noted when dams gave birth.

Sperm Dynamics : The sperm motility in cauda epididymis and density of testicular and cauda epididymis was determined (Prasad *et al.*, 1972)

Biochemical Parameters : The total protein (Lowry *et al.*, 1951), sialic acid (Warren, 1959), Glycogen (Montgomery, 1957) and Cholesterol (Zlatkis *et al.*, 1953) were assessed. Also, acid and alkaline phosphatase enzymatic activity was determined by King's Method, (1959).

Hormonal Analysis : Radioimmunoassay of testosterone level was also performed (Belanger *et al.*, 1980)

Statistical Analysis : The data were analyzed statistically by using Student's 't' test (Gad and Weil, 1982) and the significance of differences was set at $P \leq 0.01$ and $P \leq 0.001$.

Results

Body and Organ Weights : There was no significant difference in body weight at the end of the experimental period among the treated groups. However, the weight of testis, epididymis ($P \leq 0.001$), ventral prostate and seminal vesicle ($P \leq 0.01$) were decreased significantly (Fig. 1).

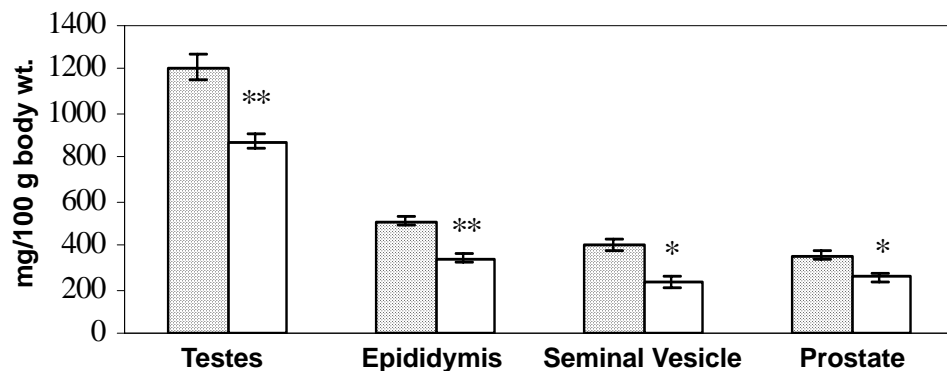


Fig. 1 : Changes in Organ Weights after Mancozeb treatment

Sperm Dynamics and Fertility : A significant decrease in sperm density in testis and cauda epididymis was observed ($P \leq 0.001$) after Mancozeb treatment (Fig. 2). Also, the sperm motility in cauda epididymis was severely impaired ($P \leq 0.001$) and fertility test showed 80% negative fertility (Fig. 3).

(million/ml)

Fig. 2 : Altered sperm density in testes and cauda epididymis after Mancozeb treatment

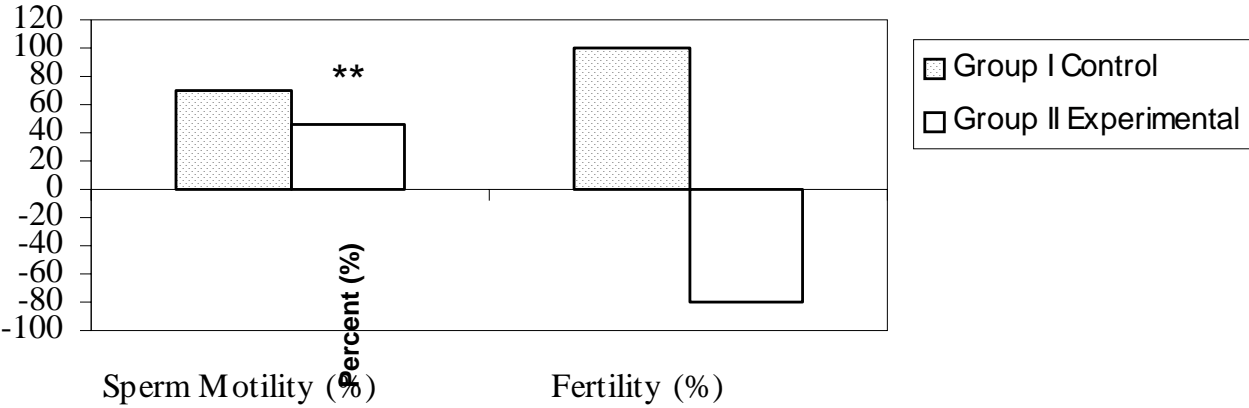


Fig. 3 : Altered sperm motility in cauda epididymis and fertility test after Mancozeb treatment

Biochemical Changes : A marked reduction in sialic acid and glycogen content of testes was observed ($P \leq 0.01$) whereas testicular cholesterol and protein increased ($P \leq 0.01$, $P \leq 0.001$) significantly (Table 1). Also a marked decline ($P \leq 0.01$) in testosterone level and alkaline phosphatase activity has been observed whereas acid phosphatase activity increased significantly ($P \leq 0.01$) (Table 2).

TABLE 1 : Biochemical Changes In Testes After Mancozeb Treatment

Treatment	Protein	Sialic acid	Cholesterol	Glycogen
– mg / g –				
Group I Control (Vehicle only)	249.97 ± 1.922	4.23 ± 0.067	8.00 ± 0.707	2.50 ± 0.190
Group II Experimental (500 mg/kg b.wt. of Mancozeb for 30 days)	302.19 ** ± 4.968	3.90* ± 0.042	10.0* ± 1.11	1.68* ± 0.203

TABLE 2 : Changes in Serum Analysis after Mancozeb Treatment

Treatment	Acid Phosphatase	Alkaline Phosphatase	Testosterone (mg/ml)
(KA units)			
Group I Control (Vehicle only)	4.59 ± 2.28	64.75 ± 2.28	2.45 ± 0.68
Group II Experimental (500 mg/kg b.wt. of Mancozeb for 30 days)	10.62* ± 1.19	47.20* ± 4.03	1.60* ± 0.73

* = $P \leq 0.01$

** = $P \leq 0.001$

Values ± SEM 6 determinations.

Testicular Histopathology : The control rat testis showed seminiferous tubules with all the successive stages of spermatogenesis (Fig. 4). Marked histopathological changes were observed in the seminiferous tubules after Mancozeb treatment in rats. These changes include damaged seminiferous tubules, which showed complete spermatogenic arrest, the lumen contained cellular debris and is devoid of sperms (Fig. 5).

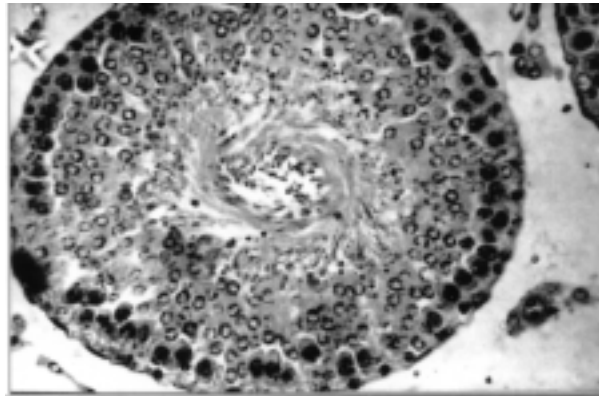


Fig. 4 : Control : Microphotograph of control rat testis showing normal histological features, with all the successive stages of spermatogenesis. Lumen filled with spermatozoa. Leydig cells are also present. (H & E 200X)

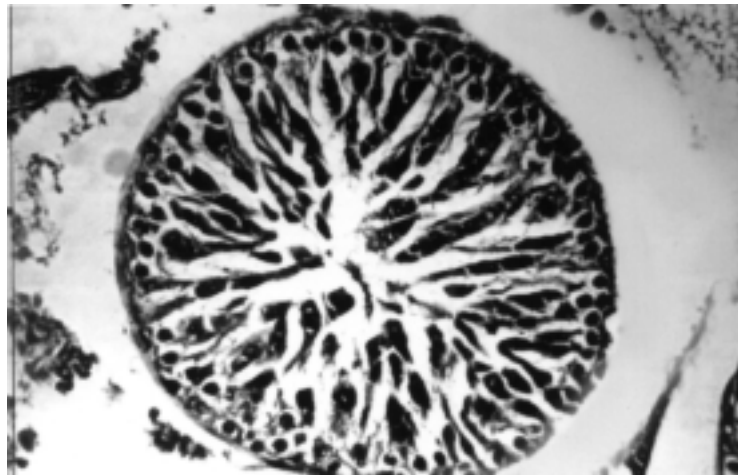


Fig. 5 : Mancozeb 500 mg/kg/b.wt. for 30 days : Photograph showing arrest of spermatogenesis, deformed and damaged tubule with degenerated Sertoli cells. Lumen is filled with cellular debris. (H&E 200X).

Discussion

Exponential increase in the production, use and disposition of chemicals have a profound impact on the environment and creates unforeseen hazards to man's well being (Desjardins, 1985 ; Chia, 2000). The present study revealed that administration of Mancozeb (500 mg/kg/ b.wt./ day for 30 days) to male rats resulted in testicular toxicity. The weight of testis is largely dependent on the mass of differentiated spermatogenic cells and the reduction in the weight of testis may be due to the decreased number of germ cells and elongated spermatids (Chapin *et al.*, 1997). The observed reduction in weight of accessory sex organs may be due to reduced bioavailability and the estrogenic and/or antiandrogenic activities of Mancozeb (Mills, 1990).

Low caudal epididymal sperm density may be due to alteration in androgen metabolism. The physiological and biochemical integrity of epididymis are dependent on androgens (Brooks, 1979). The 80% negative fertility test may be attributed to lack of forward progression and reduction in density of spermatozoa and altered biochemical *milieu* of cauda epididymis (Joshi *et al.*, 2003). Treatment with Mancozeb also changes the biochemical parameters of the reproductive tract. A fall in glycogen level may be due to interference in glucose metabolism. Fungicides induce inhibition of glycolytic enzymes, which may affect the maturational process of spermatozoa and their motility. Inhibition of glycogen synthesis eventually decreases spermatogenesis process (Desta, 1994). Reduction in testicular sialic acid content may be due to absence of spermatozoa or reduced androgen production (Dixit and Gupta, 1987). Elevation in total protein content may be due to the hepatic detoxification, which results in the inhibitory effect on the activities of enzymes involved in the androgen biotransformation (Dikshith and Datta, 1972). Increased concentration of cholesterol in testes suggests that impairment of spermatogenesis is due to decreased androgen concentration (Bedwal *et al.*, 1994).

A significant reduction in the alkaline phosphatase activity may be attributed to the decreased osteoblastic activity of bone, since it is formed and present in the osteoblasts (Naqvi and Vaishnavi, 1993). The increase in acid phosphatase activity may be the result of labialization of lysosomal

system (Zimmermann and Seff, 1982 ; Johal *et al.*, 2003). The reduction in serum testosterone demonstrated the inhibitory effects of Mancozeb on the secretion of pituitary gonadotrophins (FSH and LH), and in turn on the testosterone biosynthesis like other pesticides (Singh and Pandey, 1990). Hence, from the results it can be concluded that Mancozeb exerts testicular toxicity in albino rats.

References

- Ankley G.T. and Jensen K.M. (2001) : Description and evaluation of a short term reproduction test; *Environ. Toxicol. Chem.*, **20(6)**, 1276-1290.
- Bedwal R.S., Edwards M.S., Katoch M., Bahuguna A., Dewan R. (1994) : Histological and biochemical changes in testes of Zinc deficient Bal B/C strain mice; *Ind. J. Exp. Biol.*, **32(4)**, 243-247.
- Belanger A., Caron S. and Picard V. (1980) : Simultaneous Radioimmunoassay of progestins, androgens and estrogens in rat testis; *J. Steroid Biochem.*, **13**, 185-190.
- Bindali B.B. and Kaliwal B.B. (2002) : Anti-implantation effect of a carbamate fungicide mancozeb in albino mice; *Ind. Health*, **40(2)**, 191-197.
- Brooks De (1979) : Biochemical environment of sperm maturation. In: *The Spermatozoa*. (Eds) De Fawcett and J M Bradford. Urban and Schwargender, Baltimore. pp 23-24.
- Chapin R.E., Haris M.W. and David S.M. (1997) : The effects of perinatal juvenile methoxychlor exposure on adult rat nervous, immune and reproductive system function; *Fundam. Appl. Toxicol.*, **40**, 138-157.
- Chia S.E. (2000) : Endocrine disruptors and male reproductive function – a short review; *Ind. J. Androl.*, **23**, 45-46.
- Desjardins C. (1985) : Morphological physiological and biochemical aspects of male reproduction. In : *Reproductive Toxicology* (Ed) R L Denon (Raven Press, New York) pp 131.
- Desta B. (1994) : Ethiopian traditional herbal drugs. Part III : Antifertility activity of 70 medicinal plants; *J. Ethnopharmacol.*, **44(3)**, 199-209.
- Dikshith T.S.S. and Datta K.K. (1972) : Pathological changes induced by pesticides in the testes and liver of rats; *Exp. Pathol.*, **7**, 309-316.
- Dixit V.P. and Gupta R.S. (1987) : Antispermatic and antiandrogenic activity of *Sapindus trifoliatus* extract in intact and castrated male gerbils; *Planta Medica*, **46**, 242-246.

- Joshi S.C., Gulati N. and Gajraj A. (2005) *Asian J. Exp. Sci.*, **19**(1), 73-83
- Gad S. and Weil C.S., (1982) : Statistics for toxicologist; In: Principles and Methods of Toxicology (Ed.) H A Wallance, pp 273-320.
- Giridhar P. and Indira P. (1997) : Effects of an organophosphorous Nuvan on total lipids and lipase activity of the fresh water fish *Labeo rohita* (Hamilton); *Ind. J. Comp. Animal Physiol.*, **15**, 37-40.
- Greenlee A.R., Tammy E.M., and Richard B. L. (2004) : Low-dose agrochemicals and lawn-care pesticides induce developmental toxicity in murine preimplantation embryos; *Environ. Health Perspect.*, **112**, 703-709.
- Johal M.S., Sandhu G.S. and Kaur R. (2003) : Effect of Fenvalerate on acid and alkaline phosphatase activity in certain tissues on *Heteropneustes fossilis* (Bloch.); *Polln. Res.*, **21**(3), 309 – 313.
- Joshi S.C., Mathur R., Gajraj A. and Sharma T. (2003) : Influence of Methyl Parathion on reproductive parameters in male rats; *Env. Toxicol. and Pharmacol.*, **14**, 91-98.
- Kackar R., Srivastava M.K. and Raizada R.B. (1999) : Induction of gonadal toxicity to male rats after chronic exposure to mancozeb; *Ind Health.*, **35**(1), 104-111.
- King E.J. and Jagthesan K.N. (1959) : Method for estimation of acid alkaline phosphatases; *J. Clin. Pathol.*, **12**, 85.
- Lafuente A., Marquez N., Pousada Y., Pazo D. and Esquifino A.I. (2000) : Possible estrogenic and/or antiandrogenic effects of Methoxychlor on prolactin release in male rats; *Arch. Toxicol.*, **74**, 270-275.
- Lowry O.H., Rosenbrough D.J., Farr A.L. and Randall R.J. (1951) : Protein measurement with Folin-Phenol reagent; *J. Biol. Chem.*, **193**, 265-275.
- Mills N.C. (1990) : Androgen effects on Sertoli cells; *Int. J. Androl.*, **13**, 123-134.
- Montgomery R. (1957) : Determination of glycogen; *Arch. Biochem. Biophys.*, **67**, 378-381.
- Naqvi S.M. and Vaishnavi C. (1993) : Bioaccumulative potential and toxicity of endosulfan insecticide to non-target animals; *Comp. Bio. Chem. Physiol.*, **105**, 347-361.
- Padungtod C., Lasley B.L., Christiani D.C., Ryan L.M. and Xu M. (1998) : Reproductive hormone profile among pesticide factory workers; *J. Occup. Environ. Med.*, **40**, 1038-1047.
- Prasad M.R.N., Chinoy N.J., Kadam K.M., (1972) : Changes in succinic dehydrogenase levels in the rat epididymis under normal and altered physiological conditions; *Fertil. Steril.*, **23**, 186-190.
- Singh S.K. and Pandey R.S. (1990) : Effect of subchronic Endosulfan exposure on plasma gonadotrophins, testosterone, testicular testosterone and enzyme of androgen biosynthesis in rat; *Ind. J. Exp. Biol.*, **28**, 953-956.

Testicular Toxicity of Mancozeb

Skjei E. and Donald W.M. (1983) : Of mice and molecules, Technology and Human survival, 1st edition (The Dial Press, New York) pp 178.

Warren L. (1959) : The thiobarbituric acid assay of sialic acid; *J. Biol. Chem.*, **234**, 1971-1975.

WHO (1997) : Guidelines for poison control Geneva: WHO, in collaboration with UNEP and ILO , **3**.

Zimmermann H.J. and Seff L.B. (1982) : Enzymes in hepatic disease. In : Diagnostic enzymology (E L Coodley Ed) Lea and Febiger, Philadelphia pp 1.

Zlatkis A., Zak B. and Boyle A.J. (1953) : A new method for direct determination of serum cholesterol; *J. Lab. Clin. Med.*, **41** , 486-492.